

# Pelvic endometriosis presenting with urinary symptoms: a case report

Temuçin Şenkul (\*), Ferhat Ateş (\*), Cüneyt Adayener (\*), Hasan Soydan (\*), Levent Tütüncü (\*\*), Kadir Baykal (\*)

## SUMMARY

Ureteral obstruction secondary to endometriosis is a relatively rare condition. We present a case of incipient pelvic endometriosis presenting with urinary symptoms. A 27-year-old, nulligravid female patient admitted to our clinic with symptoms suggesting pyelonephritis. Radiological studies did not reveal urolithiasis. However, computerized tomography and magnetic resonance imaging demonstrated adnexial mass and left ureterohydronephrosis, thus leading to open surgery. During surgical exploration bicornuate uterus, myoma and a periureteral fibrotic mass were excised and end-to-end ureteral anastomosis was performed. Interestingly, the histopathological diagnosis of the periureteral fibrous tissue was endometriosis. Fast recovery was observed in the functions of impaired left kidney during early postoperative follow-up. During their daily practices urologists should be aware of ureteral stricture due to endometriosis especially in premenopausal women with dilated collective system. Kidney protective approaches should be the initial choice while managing ureteral endometriosis in women in child bearing age.

**Key words:** Endometriosis, surgical treatment, urinary obstruction

## ÖZET

**Üriner semptomlarla ortaya çıkan pelvik endometriyozis: olgu sunumu**  
Endometriyozis nedeniyle ortaya çıkan üreter tıkanıklığı nispeten nadir bir durumdur. Biz üriner semptomlarla ortaya çıkan yanıtıcı bir endometriyozis olgusunu sunuyoruz. Yirmi yedi yaşında hiç doğum yapmamış bir bayan hasta, kliniğimize piyelonefrit tanısını düşündüren belirtilerle başvurdu. Radyolojik incelemede üriner taşı ait bulguya rastlanmadı. Bununla birlikte bilgisayarlı tomografi ve manyetik rezonans görüntülemeye adneksiyal kitle ve sol üreterohidronefroz saptandı, bu yüzden açık cerrahi uygulanmasına karar verildi. Cerrahi girişimle bikornuat uterus, miyom ve üreter çevresindeki fibrotik kitle çıkarıldı ve uç-uç üreter anastomozu uygulandı. İlginç olarak üreter çevresindeki fibrotik dokunun histopatolojik tanısı endometriyozis idi. Ameliyat sonrası takipte erken dönemde bozulmuş sol böbrek fonksiyonlarının hızla düzeldiği gözlemlendi. Ürologlar günlük pratiklerinde özellikle menopoz öncesi genişlemiş toplayıcı sistemi olan kadınlarda endometriyozise bağlı gelişmiş olabilecek üreteral darlıklara karşı uyanık bulunmalıdır. Doğurgan yaşta kadınlarda üreteral endometriyozisin tedavisinde böbrek koruyucu yaklaşımlar ilk seçenek olmalıdır.

**Anahtar kelimeler:** Endometriyozis, cerrahi tedavi, üriner tıkanıklık

## Introduction

The presence of active endometrial tissue outside the uterine cavity is defined as endometriosis. It is the second most common pelvic pathology in females with an incidence of approximately 15% (1-3). Genitourinary tract involvement has been reported to have an incidence of 1.2%, with the peak age of incidence being between 40 and 44 years. Ureteral involvement accounts for only a small minority of cases (0.1–0.4%), and can be regarded as a rare occurrence. Although ureteral obstruction is a rare complication of endometriosis, early diagnosis and treatment of urinary tract endometriosis is necessary to avoid loss of renal function (4). We herein present the diagnosis and treatment of an ureteral endometriosis causing ureterohydronephrosis and deterioration of renal function.

## Case Report

A 27-year-old nulligravid female presented to our clinic with left flank pain, fever and weakness. Her physical examination did not reveal any pathology except for left costovertebral tenderness. Serum urea and creatinin levels were 34 mg/dl and 1.32 mg/dl, respectively. White blood cell (WBC) was 27000/ml and urine analysis revealed pyuria. In kidney ureter bladder (KUB) X-ray, a 0.5 cm of opacity localized to her left side of pelvis was noticed. She was hospitalized and antibiotherapy was started. Her abdominal ultrasound scan revealed a significant left ureterohydronephrosis and the left ovary was 4x4x2.5 cm with parenchymal heterogeneity, hence a gynecological consultation was requested. Her gynecologic examination was normal. Carcinoembriogenic antigen CA19-9 and CA15-3 levels were 194.3 U/ml (normal range 0-39 U/ml) and 60.1 U/ml (normal range 0-25 U/ml), respectively. A thoracoabdominopelvic noncontrast computerized tomography (CT) was planned due to high levels of serum creatinin. A thorax and abdomino-pelvic CT re-

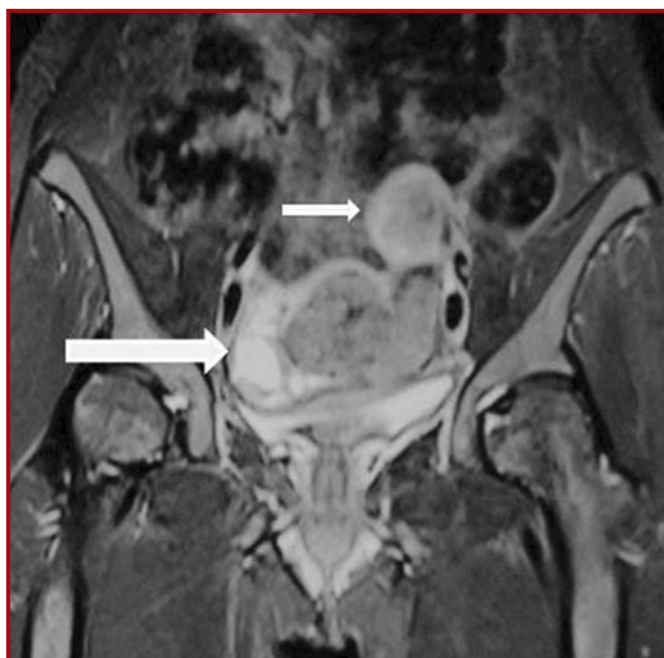\* Department of Urology, Gülhane Military Medical Faculty Haydarpaşa Training Hospital

\*\*Department of Obstetrics and Gynecology, Gülhane Military Medical Faculty Haydarpaşa Training Hospital

**Reprint request:** Dr. Ferhat Ateş, Department of Urology, Gulhane Military Medical Faculty Haydarpaşa Training Hospital, Üsküdar-34668, İstanbul  
**E-mail:** drferhatates@yahoo.com

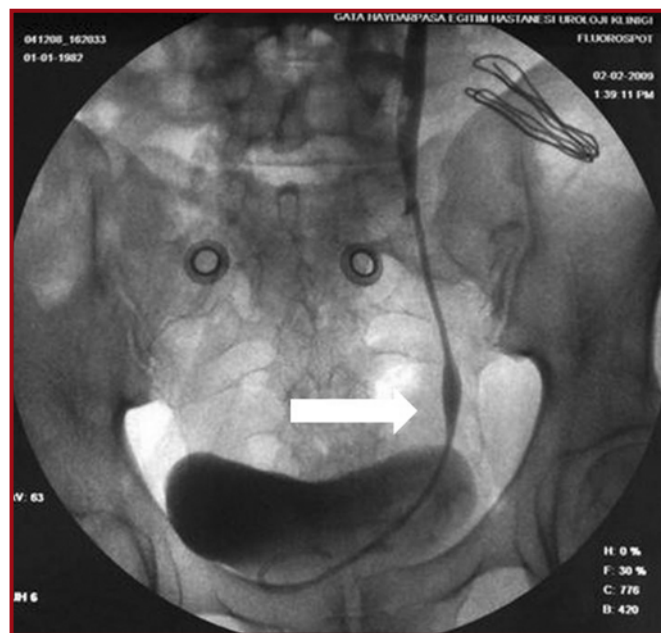
**Date submitted:** January 14, 2010 • **Date accepted:** September 02, 2010

vealed minimal pleural effusion, an atelectasis in the basal segments of the lungs and grade 2 ureterohydronephrosis on the left side but no findings of calculus at left renoureteral unit. A cystic lesion of 6 cm in diameter adjacent to uterus on the right side and a 4 cm solid mass on the left-anterior side of the uterus were reported. The relationship of the latter mass with the main vascular structure could not be clearly explained. After the antimicrobial therapy, the WBC, pyuria and creatinin levels returned to normal and a diagnostic ureteroscopy was performed. During the left ureteroscopy, approximately at the 10th cm of the ureter there was a serious stricture and kinking, obliterating the upward access with neither an ureteroscope nor with a double J stent. Her cystoscopic evaluation was normal. A left percutaneous nephrostomy was placed and the left antegrad ureterography revealed a serious obstruction at the level of the angulation and the solid mass previously detected with the CT scan. A parenchymal loss and reduced level of activity were reported in dimercaptosuccinic acid (DMSA) scintigraphy of the left kidney with a 15% of total renal function. A magnetic resonance imaging of the pelvic region revealed a myoma in the uterus and multiple hemorrhagic cysts in both ovaries (Figure 1). A reasonable explanation for the elevated CA levels could not be made. Approximately 1000 cc of daily urine was collected from left nephrostomy and an exploration was planned together with the Department of Gynecology. In operation, the distal part of the left ureter was found to be surrounded with a fibrous mass of 3x3 cm in di-



**Figure 1.** Pelvic magnetic resonance imaging of the case revealed a myoma in uterus (small arrow) and multiple hemorrhagic cysts in ovaries (big arrow)

ameter and tortuosed at the level where it crossed the iliac artery. When peritoneum was opened in order to see the distal part of the left ureter, it was observed that the left ovary and the adnexial structures were not grown, but a rudimentary horn and a myoma of 5 cm in diameter on the left side of the uterus were seen. First of all, horn excision and myomectomy were applied. The solid mass and the related distal part of ureter were excised completely and ureteroureterostomy was performed via a double J (DJ) catheter. Nephrostomy catheter was extracted after the ureterovesical passage was seen on antegrade ureterography on the 7th postoperative day (Figure 2). One month later there was no dilation in the left collecting system in sonographic evaluation and DJ catheter was extracted. Her intravenous urography was normal on the 45th postoperative day with nephrogram and pyelogram phases and ureterovesical passage. The rudimentary horn revealed a regular myometrium, the excised myoma of uterus was reported as leiomyoma and the fibrotic mass was an endometriosis externa on the pathologic evaluation. The mercapto acetyl triglycine (MAG-3) scintigraphy on the postoperative 3rd month reported that the left kidney has a 32% of the total renal function.



**Figure 2.** An ureterovesical passage was seen on antegrade ureterography on the 7th postoperative day. The arrow shows that the contrast material reaches into the bladder through next to the catheter

## Discussion

Endometriosis denotes ectopic localization of endometrial tissue and despite its benign nature it may spread to almost all pelvic organs reminiscent of an aggressive tumor. This disorder is not rare and can be

seen in 10-20% of all premenopausal women although urinary system involvement is relatively less frequent (1-11%). Incidences of bladder, ureter and renal endometriosis are 40%, 5% and 1%, respectively. It has been reported that 0.1-0.4% of all cases with pelvic endometriosis involve ureter (5). Ureteral endometriosis is classified into two main groups as intrinsic and extrinsic. In intrinsic disease, ectopic endometrial tissue directly infiltrates muscle layer, lamina propria or the lumen and possibly represents lymphatic or venous spread. However, in extrinsic endometriosis, the affected layers are adventitia and periureteral connective tissue (6). According to the pathologic diagnosis, our case was assessed as extrinsic ureteral endometriosis. It is known that the extrinsic disease is more frequent (4:1), and the distal part of ureter is almost always involved (7,8).

The diagnosis of ureteral endometriosis should be considered in a patient presenting with chronic backache even in the absence of hematuria or pelvic symptoms (9). Intravenous urography and more recently, spiral computed tomography still remain important diagnostic tools for ureteral endometriosis, as they may localized the level, degree and laterality of ureteral involvement. However, urography is unable to identify the cause of an extrinsic obstruction. In the case of intrinsic endometriosis, urography may show a filling defect within the lumen of the ureter, but this finding is not specific as it can be caused by stones or transitional cell cancer (10). In women with chronic pelvic non-cyclic pain, the occurrence of endometriosis should be taken into account. In the differential diagnosis, the postoperative adhesions, pelvic varices, interstitial cystitis and irritable bowel syndrome should be considered (11).

The disease itself has a considerably silent clinical course. Antonelli stated that 38% of the patients had slight complaints and 8 out of the 13 cases were diagnosed with urinary symptoms (12). The fact that "the diagnosis of ureteral endometriosis is rather difficult" has been confirmed with the high ratio (23-47%) of renal function loss associated with this disease (13). However, the wide availability of ultrasonography and laparoscopic procedures has reduced the ratio of nephrectomy to 7% (12). While the left kidney functions of our case were negligible at the time of presentation it showed a perfect recovery soon after the urinary diversion. This significantly emphasizes that nephrectomy should be deferred particularly in young patients. In accordance with this observation, Antonelli et al. reported excellent results (improvement in renal functions in 90% of cases) following

urinary diversion which was done preoperatively in patients with ureteral endometriosis associated with serious ureterohydronephrosis (14). Interestingly, the diagnosis could be made in less than half (46%) of the cases preoperatively due to the variant presentation of the disease (12).

Vercellini and Antonelli reported that the unilateral cases were mainly at the left side. They explained this situation with the following hypothesis: the sigmoid colon is acting as a natural path allowing retrograde cell implantation from uterine cavity (15). In addition to this explanation, a congenital uterine anomaly might contribute as well. It is possible that the Mullerian duct remnants are pivotal in initializing the pathological process. In fact, the embryonic theory is still valid for the pathophysiology of endometriosis (6).

Ectopic endometrial tissue bleeds periodically, and desquamation, necrosis and fibrosis follow the hemorrhage. This process leads to ureteral stricture (12). GnRH analog therapy can also cause ureteral stricture due to the fibrosis. However, medical therapy following surgery should be considered as a prophylactic intervention in patients who did not undergo total hysterectomy and bilateral oophorectomy. Formerly, ureteral catheterization and ureterolysis were done for these patients (16,17), but no successful outcome has been reported (12).

Surgical treatment may consist of ureteroneocystostomy, laparoscopic ureterolysis, with later ureteral resection and end-to-end anastomosis, or even autotransplantation in case of ureteral relapses. Traditionally, laparotomy has been the method of choice for ureteral injuries even when the injury is identified during a laparoscopic procedure. Today, however, some urologists feel that laparotomy should be avoided as it shows a higher rate of infection and incisional hernias, longer hospital stay, and slower recovery compared with laparoscopy. It is still debated whether segmental resection and anastomosis or ureterolysis or minimal-access procedures are preferable. Recent studies suggest that laparoscopic ureterolysis can be an effective treatment option in most patients with ureteral endometriosis but that recurrence rates are not negligible. Successful application of laparoscopic surgery, even for procedures that have traditionally necessitated laparotomy, has been reported. Extensive experience with endourological techniques is prerequisite for success. The frequency of associated lesions (urinary, gynecological gastrointestinal) justifies a multidisciplinary surgical approach (10).

Segmental ureterectomy provides the removal of both endometriotic and fibrotic tissues. If there is no sign of endometriotic tissue in the distal ureter, an uretero-ureteral anastomosis can be done safely. In the case of diffuse ureteral involvement, ureteroneocystostomy would be more appropriate. Our case was treated with segmental ureterectomy and uretero-ureteral anastomosis since the ureteral endometriosis was present in a limited area. One might also consider that an underlying congenital anomaly could have contributed the clinical setting. Hence, medical treatment in the case of recurrence and a close follow-up will be appropriate for this young woman.

In conclusion, urologists should be aware of ureteral stricture due to endometriosis especially in premenopausal women with dilated collective system during their daily practices. It should be kept in mind that this pathology may accompany uterine anomalies. As highlighted in this case report, kidney protective approaches should be the initial choice while managing ureteral endometriosis in women in child bearing age.

## References

1. Vessey MP, Villard-Mackintosh L, Painter R. Epidemiology of endometriosis in women attending family planning clinics. *BMJ* 1993; 306: 182-184.
2. Stillwell TJ, Kramer SA, Lee RA. Endometriosis of ureter. *Urology* 1986; 28: 81-85.
3. Plous RH, Sunshine R, Goldman H, Schwartz IS. Ureteral endometriosis in post-menopausal women. *Urology* 1985; 26: 408-411.
4. Juan HC, Yeh HC, Hsiao HL, Yang SF, Wu WJ. Endoscopic management of a ureteral obstruction caused by endometriosis: a case report. *Kaohsiung J Med Sci* 2009; 25: 217-221.
5. Jubanyik KJ, Comite F. Extrapelvic endometriosis. *Clin Obstet Gynecol North Am* 1997; 24: 411-440.
6. Comiter CV. Endometriosis of the urinary tract. *Urol Clin North Am* 2002; 29: 625-635.
7. Fujita K. Endometriosis of the ureter. *J Urol* 1976; 116: 664-666.
8. Kane C, Droulin P. Obstructive uropathy associated with endometriosis. *Am J Obstet Gynecol* 1985; 151: 207-211.
9. Hsieh MF, Wu IW, Tsai CJ, Huang SS, Chang LC, Wu MS. Ureteral endometriosis with obstructive uropathy. *Intern Med* 2010; 49: 573-576.
10. Ponticelli C, Graziani G, Montanari E. Ureteral endometriosis: a rare and underdiagnosed cause of kidney dysfunction. *Nephron Clin Pract* 2010; 114: 89-93.
11. Vercellini P, Somigliana E, Viganò P, Abbiati A, Barbara G, Fedele L. Chronic pelvic pain in women: etiology, pathogenesis and diagnostic approach. *Gynecol Endocrinol* 2009; 25: 149-158.
12. Antonelli A, Simeone C, Frego E, Minini G, Biannchi U, Cunico SC. Surgical treatment of ureteral obstruction from endometriosis: our experience with thirteen cases. *Int Urogynecol J* 2004; 15: 407-412.
13. Rozuer R, Deval B, Muray JM. Endometriose ureterale: un propos de 3 cas. Conduite diagnostique et therapeutique. *Revue de la litterature. Contracept Fertil Sex* 1998; 26: 173-178.
14. Antonelli A, Simeone C, Zani D, et al. Clinical aspects and surgical treatment of urinary tract endometriosis: our experience with 31 cases. *Eur Urol* 2006; 49: 1093-1098.
15. Vercellini P, Pisacreta A, Pesole A, Vicentini S, Stellato G, Crosignani PG. Is ureteral endometriosis an asymmetric disease? *BJOG* 2000; 107: 559-561.
16. Stebbing JF, Notley RG. Noncalculous obstruction due to involvement of the ureter in endometriosis. *Eur Urol* 1995; 28: 122-125.
17. Nezhat C, Nezhat F, Nezhat CH. Urinary tract endometriosis treated by laparoscopy. *Fertil Steril* 1996; 66: 920-924.