

Stereotactic radiosurgery for intracranial tumors: a single center experience

Ferrat Dinçođlan (*), Ömer Sađer (*), Hakan Gamsız (*), Bora Uysal (*), Selçuk Demiral (*), Bahar Dirican (*), Kaan Oysul (*), Serdar Sürenkök (*), Sait Şirin (**), Murat Beyzadeođlu (*)

SUMMARY

Stereotactic radiosurgery is being increasingly used for the treatment of both benign and malignant disorders such as brain metastasis, spinal cord tumors, intracranial blood vessel abnormalities and neurological/functional problems such as Parkinson's disease, epilepsy, obsessive-compulsive disorder and trigeminal neuralgia. The purpose of this report was to present our experience at the Department of Radiation Oncology of Gülhane Military Medical Faculty using linear accelerator-based stereotactic radiosurgery technology and to examine the efficacy and safety of radiosurgery in the treatment of the most common intracranial tumors and functional disorders. More than 400 treatments have been performed using stereotactic radiosurgery between 1998 and 2010 for intracranial benign and malignant lesions along with functional disorders. In this study, patients treated using stereotactic radiosurgery were retrospectively examined to determine the radiosurgical parameters, duration of follow-up, treatment response and patient survival. Functional, radiological and clinical improvement was achieved in most of the patients treated using stereotactic radiosurgery either by improving local control, providing decompression, obliteration of pathologic vessels, or preventing hemorrhages. Stereotactic radiosurgery offers a safe and effective treatment approach for intracranial benign/malignant lesions and functional disorders leading to improved local control, survival and quality of life.

Key words: *Intracranial tumors, linear accelerator, stereotactic radiosurgery*

ÖZET

İntrakraniyal tümörlerde stereotaktik radyocerrahi: tek merkez deneyimi
Stereotaktik radyocerrahi beyin metastazı, spinal kord tümörleri, intrakraniyal damar anomalileri gibi benign ve malign bozukluklar ile Parkinson hastalığı, epilepsi, obsesif kompulsif bozukluk ve trigeminal nevralji gibi nörolojik/fonksiyonel problemlerin tedavisinde giderek artan sıklıkta kullanılmaktadır. Bu çalışmanın amacı Gülhane Askeri Tıp Fakültesi Radyasyon Onkolojisi Anabilim Dalı'nın lineer akseleratör-tabanlı stereotaktik radyocerrahi teknolojisini ile olan deneyimlerini sunmak ve en sık görülen intrakraniyal tümör ve fonksiyonel bozuklukların tedavisinde radyocerrahinin etkinliğini ve güvenilirliğini araştırmaktır. İntrakraniyal benign ve malign lezyonlar ile fonksiyonel bozuklukların 1998 ile 2010 yılları arasındaki stereotaktik radyocerrahisinde 400'den fazla tedavi uygulanmıştır. Bu çalışmada radyocerrahiyle tedavi edilen hastalar radyocerrahi parametreleri, tedavi sonrası takip süresi, tedavi cevabı ve sağkalım açısından retrospektif olarak incelenmiştir. Sterotaktik radyocerrahi ile tedavi edilmiş hastaların çoğunda lokal kontrolün düzelmesi, dekompresyon sağlanması, patolojik damarların obliterasyonu ve kanamanın önlenmesi ile fonksiyonel, radyolojik ve klinik iyileşme sağlanmıştır. Stereotaktik radyocerrahi intrakraniyal benign/malign lezyonlar ile fonksiyonel bozuklukların lokal kontrolünü, hasta yaşamını ve hasta yaşam kalitesini artıran güvenilir ve etkili bir tedavi yaklaşımıdır.

Anahtar kelimeler: *Intrakraniyal tümör, lineer akseleratör, stereotaktik radyocerrahi*

* Department of Radiation Oncology, Gülhane Military Medical Faculty

**Department of Neurosurgery, Gülhane Military Medical Faculty

Reprint request: Dr. Ferrat Dinçođlan, Department of Radiation Oncology, Gülhane Military Medical Faculty, Etlik-06018, Ankara, Turkey
E-mail: ferhatdincoglan@gmail.com

Date submitted: December 27, 2011 • Date accepted: January 17, 2012 • Online publication date: September 07, 2012

Introduction

Stereotactic radiosurgery (SRS), since its introduction by Lars Leksell in 1951, has been increasingly used for the treatment of both benign and malignant disorders and neurological problems such as Parkinson's disease, epilepsy, obsessive-compulsive disorder and trigeminal neuralgia (1). The primary goal of Leksell was to treat the patients deemed unsuitable for open surgery with radiation therapy as a non-invasive approach. Initial applications of SRS were performed by mounting the orthovoltage X-ray tube to a stereotactic frame for the treatment of trigeminal neuralgia. As significant progress was achieved with experimental studies, the first Gamma Knife (GK) device consisting of 179 Cobalt sources was put into service in 1968. Studies on heavy particle radiotherapy were initiated at the same period and after the introduction of Cyclotron by Ernest Lawrence in 1929, his brother performed the treatment of intracranial pathologies using helium and proton beams (2,3). However, these treatments were performed in a limited number of centers due to the high cost of the heavy ion centers and maintenance of cyclotrons. As studies on SRS progressed, Betti and Colombo adopted SRS to be performed with linear accelerators which are more cost-effective than heavy ion accelerators (4,5).

Increased clinical experience and studies led to the determination of indications for SRS and Gamma Knife, and LINAC-based SRS Technologies were comparatively evaluated. However, clinical and physical studies conducted so far have shown both methods to be precise and effective (6). The Cyberknife consisting of a linear accelerator with 6 MV energy mounted on a robotic arm has been put into service in 1984 at Stanford university and it has been used without a stereotactic frame for the treatment of intra and ex-

tracranial pathologies. Moreover, this technique allows fractionated SRS (7,8).

Many improvements achieved in computerized and real-time imaging technology, treatment planning systems and the capability of localizing and treating targets with submillimeter precision makes SRS a preferred non-invasive treatment modality (9). Highly conformal treatments with steep dose gradients achieved with SRS allows precisely focused, high-dose beams to be delivered to a small, localized area of the brain without compromising normal tissue sparing. A multidisciplinary team consisting of a radiation oncologist, neurosurgeon and medical physicist is necessary to run this highly sophisticated process. Currently, SRS is done by a variety of technologies including linear accelerators, particle beam accelerators and multisource Cobalt 60 units. Since SRS delivers highly conformal dose distributions with unacceptable geographic miss due to inaccurate delineation, it needs neuroradiological expertise and collaboration for precise target and organs-at-risk (OAR) localization. Linear accelerators, multisource Cobalt 60 units and particle beam accelerators comprise the major sources of radiation for the SRS procedure. Target coverage, dose homogeneity, target conformality and normal tissue sparing are integral aims of safe and effective SRS applications (10).

Linear accelerator-based radiosurgery is widely available throughout the world. LINAC-based SRS is done either by dedicated linear accelerator units or with linear accelerators modified for radiosurgical use. In LINAC-based SRS, intracranial targets are treated using single or multiple isocenter plans. Initially, circular collimators were used to reduce beam penumbra, which were then replaced with micro-multileaf collimators providing better conformity. In LINAC radiosurgery, multiple non-coplanar arcs may be used around an isocenter which allow contribution of many arcs to achieve a high dose at the isocenter. Micromultileaf collimation allows optimal target conformity through field shape alterations.

LINAC-based SRS has been reported to produce isodose distributions with conformity indices similar to Gamma Knife plans using multiple isocenters (11). However, a wider array of treatment options is possible with Linac sources (12). Another advantage of LINAC-based SRS is the capability of treating larger tumor volumes in several sessions. Intensity modulation may be used to further improve conformity, and

it may be combined with inverse treatment planning to optimize normal tissue sparing (13).

The purpose of this report was to describe the experience at our center using SRS technology and examine the efficacy and safety of radiosurgery in the treatment of the most intracranial tumors and functional disorders. Patients treated from 1998 to 2010 at our department of radiation oncology were retrospectively examined to determine the radiosurgical parameters, duration of follow-up review, treatment response and survival of the treated patients.

Material and Methods

Between November 1998 and December 2010, 423 patients were treated with SRS at the Department of Radiation Oncology of Gulhane Military Medical Academy. Of these 423 patients, 265 (62.6%) were male and 158 (37.4%) were female. Median age was 45 (range; 9-79) years. An informed consent was taken from each patient before treatment. Treatment decision was determined by a multidisciplinary team including experts on radiation oncology and neurosurgery. For the first 10 years, SRS planning was done with XKnife-3 (Radionics, Boston, MA, USA) and treatment was delivered by linear accelerator SL-25 (Elekta, UK). Radiosurgery planning system was then replaced with ERGO ++ (CMS, Elekta, UK) allowing Volumetric Modulated Arc Radiosurgery, whereas treatments were given by linear accelerator Synergy (Elekta, UK) with 3 mm thickness head-on dynamic micro-MLC (micro multileaf collimator). On the day of treatment, either a stereotactic frame (Leksell frame or 3D-Line frame, Elekta, UK) was affixed with 4 pins to the patient's skull under local anesthesia or a non-invasive system consisting a customized SRS mask was prepared, and a planning CT scan usually fused with a prior MRI was used for computerized treatment planning.

In the planning; either a single 360-degree 18 arcs, double 360-degree 36 arcs, four 90-degree 5 arcs or five 180-degree 48 arcs were selected to spare the critical structures around the target location. Target volume and critical structures were defined manually by both the treating radiation oncologist and neurosurgeon. Windows and levels of the treatment planning CT were adjusted to improve visualization of the target and critical structures. Coronal and sagittal images were used in addition to axial images to improve target and OAR delineation accuracy. Arc

modulation optimization algorithm (AMOA) was used to improve target coverage while sparing critical structures. All patients underwent high-precision single dose SRS using a linear accelerator with 6-MV photons. Isocenters of all patients were checked by kV-CBCT (kilovoltage Cone Beam CT) and setup verifications were done by XVI (X-ray Volumetric Imaging, Elekta, UK) system. 8 mg intravenous dexamethasone with H₂-antihistamines was used immediately after SRS.

After the completion of treatment, follow-up visits were scheduled for every patient routinely at the 2nd month for the first visit, then at 3-month intervals for the first year, at 6-month intervals for the second year, and annually thereafter including clinical examination with detailed neurological evaluation and neuroimaging with contrast-enhanced MRI. Patients were requested to inform the treating physician about any unexpected neurological worsening regardless of the follow-up schedule.

Results

A total of 423 patients with intracranial tumors were treated using LINAC-based SRS at our department between 1998 and 2010. Median age for all patients was 45 (range; 9-79) years. Of the total 423 patients, 139 (32.9%) had malignant tumors, 191 (45.2%) had benign tumors, 88 (20.8%) had vascular malformations, and 5 (1.1%) had functional disorders. Diagnosis of patients treated with SRS are shown in Table I and Figure 1. Of the 139 patients with malignant tumors, 117 (84.2%) had brain metastasis, 19 (13.7%) had recurrent glioblastoma, and 3 (2.1%) had other malignant tumors (Figure 2).

Of the 191 patients with benign tumors, 57 (29.8%) had pituitary adenomas, 53 (27.7%) had meningiomas, 52 (27.3%) had acoustic neuromas, 13 (6.8%) had craniopharyngiomas, 16 (8.4%) had other benign tumors (Figure 3).

Of the 88 patients with vascular malformations, 51 (58%) had arteriovenous malformations (AVM), and 37 (42%) had cavernomas.

In addition to these 418 patients aforementioned, functional disorders including obsessive-compulsive disorder in 2 patients (40%) and trigeminal neuralgia in 3 patients (60%) were treated using SRS (Table I).

Brain metastasis: The pseudospherical shape of brain metastases makes these lesions optimal targets for radiosurgery. The frequent location of the meta-

static lesions at the junction of gray and white matter allows the application of higher single doses since this region is relatively noneloquent. MRI, which is increasingly being used for neuroimaging, allows the detection of smaller lesions (<3 cm) suitable for SRS. Many studies have reported a local tumor control of 25% to 97% and a median survival of 6-27 months showing the efficiency of SRS in the treatment of brain metastasis (14-25).

Between 1998 and 2010, 117 patients (68 male, 49 female) were treated for brain metastases at our department. Of these 117 patients, 77 (65.8%) were treated using whole brain radiation therapy (WBRT)+SRS, 21 (17.9%) were treated with surgery+WBRT+SRS, 12 (10.3%) were treated with surgery+SRS to the resection cavity, and 7 (6%) with SRS only. Median age was 53 (range; 23-79) years. Median dose for SRS was 18 Gy (range; 10-20 Gy) prescribed to the 84%-96% isodose line encompassing the target. Median overall survival was 9.3 (range; 4-22) months.

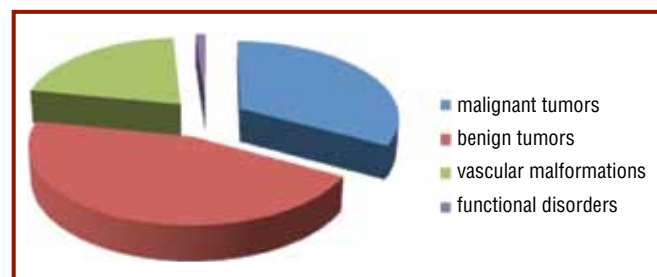


Figure 1. Diagnosis of patients treated with stereotactic radiosurgery

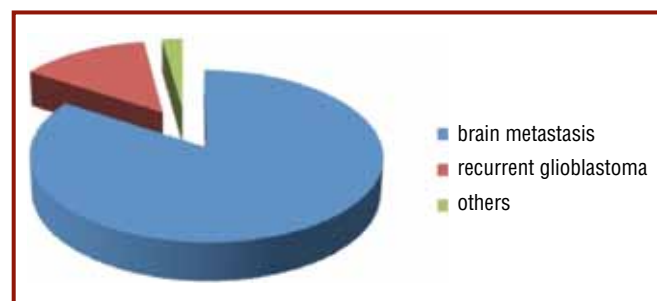


Figure 2. Malignant tumors treated using stereotactic radiosurgery

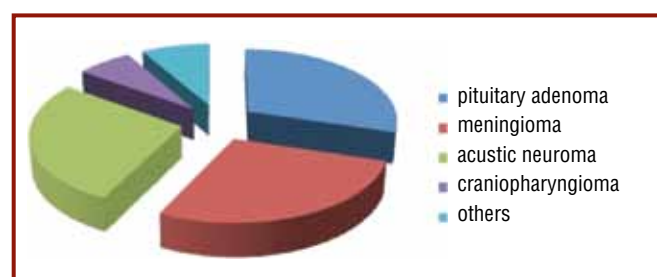


Figure 3. Benign tumors treated using stereotactic radiosurgery

Table I. Diagnosis of patients treated with stereotactic radiosurgery

<i>Diagnosis</i>	<i>Number</i>	<i>%</i>	<i>% of total 423</i>
Malignant tumors	139	100	
Brain metastasis	117	84.2	32.9
Recurrent glioblastoma	19	13.7	
Other	3	2.1	
Benign tumors	191	100	
Pituitary adenomas	57	29.8	45.2
Meningiomas	53	27.7	
Acoustic neuroma	52	27.3	
Craniopharyngioma	13	6.8	
Other	16	8.4	
Vascular malformations	88	100	
Arteriovenous malformation	51	58	20.8
Cavernoma	37	42	
Functional disorders	5	100	
Trigeminal neuralgia	3	60	1.1
Obsessive-compulsive disorder	2	40	
Total	423	100	100

Recurrent glioblastoma: The treatment of recurrent glioblastomas comprise a therapeutic challenge in neurooncology. Despite many advances achieved so far, the prognosis remains to be poor and many patients with glioblastoma still die of progressive recurrent disease usually within the initial treatment field. Between 1998 and 2010, 19 patients (13 male, 6 female) with locally-recurrent glioblastoma were treated using single-dose SRS at our department. The median marginal dose was 18 (range; 13-20) Gy prescribed to the 86%-97% isodose line encompassing the PTV. Median time interval from primary glioblastoma diagnosis to locally-recurrent disease was 9 (range; 2-49) months. Median progression-free survival was 5.7 months and median overall survival was 9.3 months after SRS. LINAC-based single-dose SRS is safe and effective in the treatment of locally-recurrent glioblastoma. It is tolerated well and allows shorter hospitalization times.

Pituitary adenomas: Pituitary adenomas are classified as microadenomas and macroadenomas according to their size, and also classified as functioning and non-functioning tumors according to their functional status. They are usually benign, slow-growing tumors confined to sella turcica, however tumor growth may lead to symptoms including visual disturbances particularly in the form of bitemporal visual field loss,

headache and hypopituitarism through invasion of surrounding critical structures. The primary treatment goals in the treatment of pituitary adenomas are to control tumor growth and normalize excess hormone secretion in functioning tumors. Between 1998 and 2010, 57 patients with pituitary adenomas were treated using SRS at our department. 30 patients were male and 27 patients were female. Median age was 40 (range; 19-57) years. Median dose was 13 (range; 10-16) Gy prescribed to the 86%-94% isodose line encompassing the target. 38 lesions (66.7%) were non-functioning, whereas 19 lesions (33.3%) were functioning adenomas. Of the 19 functioning adenomas, 8 (14%) were prolactin secreting, 7 (12.3%) were growth-hormone secreting and 4 (7%) were corticotropin secreting. Of the 57 lesions treated, follow-up with MRI revealed radiologic regression in 25 (43.9%) lesions, no radiologic change in 23 (40.3%) patients, thus 48 patients (84.2%) were locally controlled. Clinical improvement was also observed in most of the patients after SRS. Of the 19 patients with functioning pituitary adenomas, 13 patients had available biochemical follow-up and biochemical complete response was achieved in 8 of these 13 patients (%42.1). Adjuvant SRS after surgery improves local tumor control and biochemical control in patients with pituitary adenomas.

Meningiomas: Meningiomas arise from the arachnoid cap cells. These tumors are usually slow-growing and benign tumors, which may be totally removed surgically in general. For lesions such as skull base meningiomas, the close proximity of the tumor to the critical structures including cranial nerves or the optic pathways usually preclude complete surgical resection. SRS has been used for primary and adjuvant treatment of meningiomas since 1990s. Control rates with SRS ranging between 86% and 98% have been reported (26-36). SRS may be a good treatment alternative when factors including tumor location, size, patient's inoperability status, and neurological symptoms preclude surgery. Between 1998 and 2010, 53 (32 female and 21 male) patients with meningiomas were treated using SRS at our department. Median dose of 12 (range; 10-18) Gy was prescribed to the 87%-97% isodose line encompassing the target. Local control rate was 86% in the 48 patients with periodical follow-up. LINAC-based SRS offers a safe and effective alternative to surgery in intracranial benign meningiomas with high local control rates and low morbidity.

Acoustic neuromas: Acoustic neuromas commonly originate from the transition zone between central oligodendroglial cells and peripheral schwann cells within the vestibular part of cranial nerve VIII. Vestibular schwannomas comprise 80%-90% of all cerebellopontine angle tumors in adults with a median initial diagnosis age of about 50 years (37). A considerable amount of acoustic neuromas may not become clinically evident due to the slow growth pattern of the disease. Hearing loss in patients with acoustic neuroma is usually chronic and develops in years. 95% of patients with cochlear nerve involvement develop hearing loss and tinnitus. Treatment of acoustic neuromas targets to achieve local control while preserving hearing without compromising trigeminal and facial nerve functionality. 52 patients (32 male and 20 female) with acoustic neuromas were treated using SRS at our department between 1998 and 2010. Median age was 45 (range; 20-77) years. Median dose was 12 (range; 10-12) Gy prescribed to the 88%-95% isodose line encompassing the target. Overall radiological tumor control was 88%. Treatment of acoustic neuromas using LINAC-based single dose SRS is safe and effective.

Craniopharyngiomas: Craniopharyngiomas are rare benign tumors arising near the pituitary gland and pituitary stalk which may be purely solid, purely cystic

or mixed solid and cystic in structure. Depending on the location, size and growth rate of the tumor, pituitary hormone deficiency, visual field loss, obstructive hydrocephalus and extraocular cranial nerve palsies may occur. The management of craniopharyngiomas usually requires a multimodality approach since local recurrence is common and surgery is rarely curative owing to the critical location of the tumor in most of the cases (38,39). 13 patients (9 male, 4 female) with craniopharyngioma were treated using LINAC-based single dose SRS between 1998 and 2010. Median age was 37 (range; 9-61) years. The median marginal dose was 12.5 (range; 10-18) Gy prescribed to the 86%-92% isodose line encompassing the tumor. The overall local control rate was 87% at 1 year, 78% at 3 years and 64% at 5 years. SRS is a safe and effective treatment option in the management of recurrent or residual craniopharyngiomas. It may also be used as complementary initial treatment after incomplete resection to avoid the higher risk of radical surgery in selected patients.

Arteriovenous malformations: Arteriovenous malformations are developmental malformations of the arteriovenous system which are composed of abnormal arterial clusters and arterialized vessels with irregular vessel walls. They are usually asymptomatic but headache and seizure episodes may be seen when they become symptomatic. Major complications of AVM are hemorrhage due to the fragile structure of vessel walls and hemorrhage-related complications. The primary goal of treatment is to prevent hemorrhage. Lifetime risk of hemorrhage for AVMs is 40% and yearly hemorrhage rate is 2%-4% (40-43). Radiosurgery is a widely accepted treatment modality for intracranial AVMs. Surgical resection is not an optimal treatment approach for deep-seated AVMs or those located in eloquent areas owing to the risk of damage to surrounding brain parenchyma; radiosurgery is a good treatment alternative for these lesions. 51 patients (28 male, 23 female) with AVM were treated using SRS between 1998 and 2010. Median age was 32 (range; 13-58) years. Spetzler-Martin AVM classification was grade I in 8 patients (15.7%), grade II in 8 patients (15.7%), grade III in 19 patients (37.2%), grade IV in 13 patients (25.5%) and grade V in 3 patients (5.9%). Median maximum diameter of preSRS AVM was 23 (range; 8-52) mm. Median marginal dose was 18 (range; 12-20) Gy. 37 patients (72.5%) out of 51 patients completed 3-year follow up and an-

giograms for these patients demonstrated complete obliteration in 27 patients (73%), >80% obliteration in 7 patients (18.9%) and <80% obliteration in 3 patients (8.1%). Linac-based SRS is a safe and effective treatment modality in the management of cerebral AVMs.

Cavernomas: Cavernomas are rare hamartomas of vascular structures (44). Cavernomas are usually asymptomatic (45,46); but infarcts may occur in the setting of intralesional thrombosis (47). The most common clinical symptoms include epilepsy, intracerebral hemorrhage, focal neurologic signs, and headache. Treatment strategies for cavernomas generally include surveillance in asymptomatic patients with lesions located in surgically inaccessible areas, surgery in symptomatic patients with lesions located in surgically accessible areas, and radiosurgery in progressively symptomatic patients with lesions located in surgically inaccessible areas. 37 patients (27 male and 10 female) with cavernomas were treated between 1998 and 2010 using single dose LINAC-based SRS. Median dose prescribed to the 87%-94% isodose line was 15 (range; 14-18) Gy. Hemorrhage was not observed in any of the total 37 patients at a median follow-up of 62 (range; 18-114) months. Clinical improvement was observed in most of the patients with symptoms before SRS. Treatment with SRS was well tolerated by all patients. Linac-based single dose radiosurgery is safe and effective in the management of cavernomas. By decreasing the hemorrhage risk, SRS offers an effective treatment alternative for high risk patients with symptomatic cavernomas in whom the lesions are surgically inaccessible.

Trigeminal neuralgia: Trigeminal neuralgia, also named "tic douloureux", is the facial pain which is usually one-sided in the distribution of 5th cranial nerve. The most commonly known cause of trigeminal neuralgia is the vascular compression of the trigeminal nerve (48,49). The vascular compression is in superior cerebellar artery in 64% of the cases (50). Vascular compression leads to continuous demyelination and remyelination cycles which causes myelination abnormalities of the nerve. High frequency ectopic impulses from this impaired myelination area may cause pain (51).

Medical treatment is the first step in trigeminal neuralgia that may lead to committing suicides. However, additional therapies are required in the setting of temporary response or refractory pain despite medi-

cal treatment. Carbamazepine, fenitoin, gabapentin, and baclofen may be used as medical treatment (52). Invasive interventions are done when medical treatment is ineffective or when the side effects of medical treatment are unacceptable. Interventional procedures include percutaneous radiofrequency (RF) rhizotomy, percutaneous glycerol rhizotomy, percutaneous balloon microcompression and microvascular decompression (MVD). MVD is the most invasive procedure, however, repeating pain rates are lower with MVD (53). Relapse is observed approximately in 30% of patients initially treated with MVD.

Studies investigating the role of radiosurgery have rapidly increased regarding the poor results in pain control with invasive procedures, high rates of relapse and remarkable morbidity. Pain relief with radiosurgery in trigeminal neuralgia was first reported in 1951 (1,54). A subsequent study revealed complete pain responses of 58%-70% with ≥ 70 Gy single dose radiosurgery (50).

Between November 2008 and December 2010, 3 patients were treated using single dose LINAC-based SRS at our department. All 3 patients had refractory pain despite medical treatment. They had a history of pain for a median of 5.5 (range; 2-13) years. 70 Gy single dose was prescribed to the 76%-80% isodose line (Figure 4). Follow-up 1 month after discontinuation of medical treatment revealed complete resolution of pain in every individual patient. No trigeminal neuralgia relapse was observed in patients during the total one-year follow-up for all three patients.

Obsessive compulsive disorder (OCD): SRS targets the anterior limb of internal capsule in the treatment of OCD to perform a capsulotomy in right hemisphere, left hemisphere, or both (Figure 5) (55). Two patients with medical treatment refractory OCD were treated with LINAC-based SRS at our department during the period of our retrospective study and clinical improvement was completely achieved in one patient and partially in the other one confirmed with psychiatric evaluation in the post-treatment 6th month follow-up examination. The dose to the anterior limbs of the internal capsules was 70 Gy to the 70% isodose in both patients.

Recent years have witnessed the widely adapted and accelerated use of SRS as a safe and useful alternative to both conventional radiotherapy and neurosurgery for many benign and malignant brain lesions. Improvements achieved in computerized,

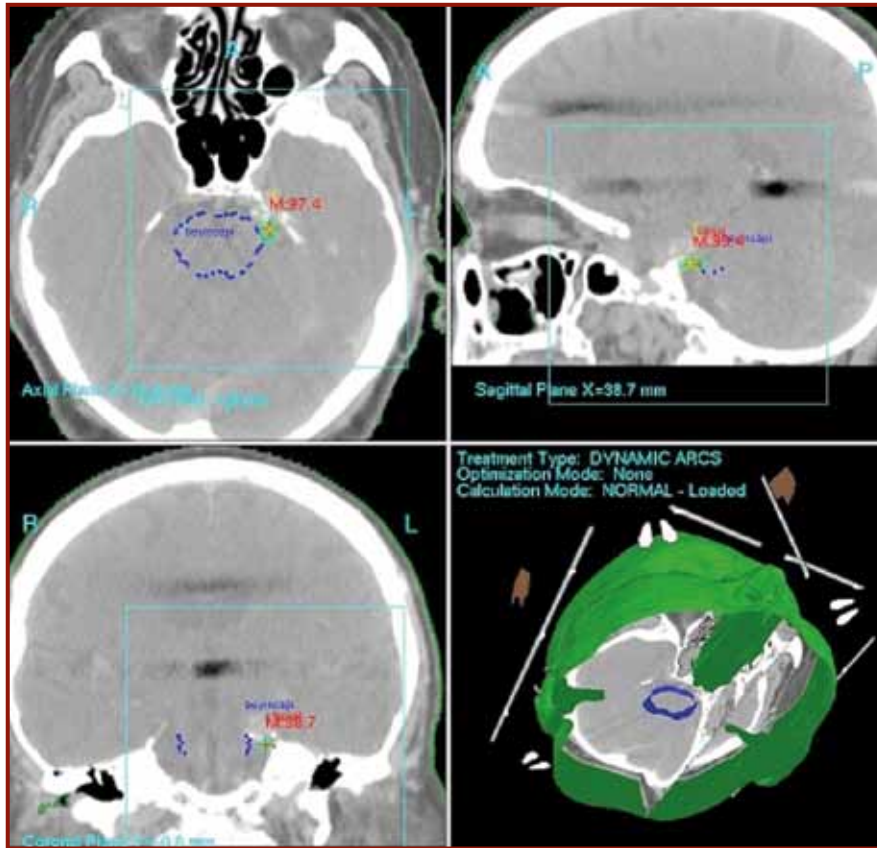


Figure 4. Stereotactic radiosurgery planning for trigeminal neuralgia

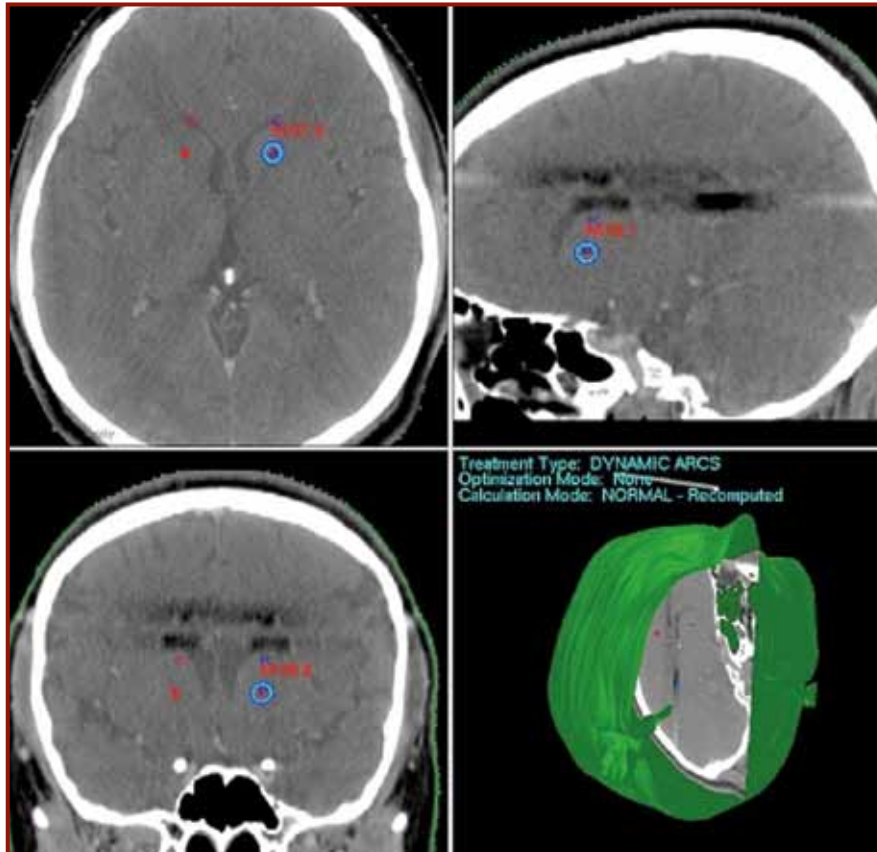


Figure 5. Left anterior limb of the internal capsule stereotactic radiosurgery planning for obsessive compulsive disorder therapy

real-time imaging technology, treatment planning systems and the capability of localizing and treating targets with submillimeter precision makes SRS a preferred treatment modality. Indications for SRS are expanding at a high speed in pace with developments in technology, thus this highly sophisticated treatment modality has the potential of changing the current standards of care in neurooncology in the near future. Its effectiveness as an adjuvant therapy has been demonstrated in many intracranial pathologies. However, randomized studies are warranted to place SRS as the treatment of choice for intracranial tumors in the evidence-based era of clinical oncology.

References

1. Leksell L. The stereotaxic method and radiosurgery of the brain. *Acta Chir Scand* 1951; 102: 316-319.
2. Kirn TF. Proton radiotherapy: some perspectives. *JAMA* 1988; 259: 787-788.
3. Skarsgard LD. Radiobiology with heavy charged particles: a historical review. *Phys Med* 1998; 14 (Suppl 1): 1-19.
4. Betti O, Derechinsky V. Hyperselective encephalic irradiation with a linear accelerator. *Acta Neurochir* 1984; 33: 385-390.
5. Columbo F, Benedetti A, Pozza F, et al. External stereotactic irradiation by linear accelerator. *Neurosurgery* 1985; 16: 154-160.
6. Luxton G, Petrovich Z, Jozsef G, Nedzi LA, Apuzzo ML. Stereotactic radiosurgery: principles and comparison of treatment methods. *Neurosurgery* 1993; 32: 241-259.
7. Adler JR Jr, Colombo F, Heilbrun MP, Winston K. Toward an expanded view of radiosurgery. *Neurosurgery* 2004; 55: 1374-1376.
8. Pollock BE, Lunsford LD. A call to define stereotactic radiosurgery. *Neurosurgery* 2004; 55: 1371-373.
9. Jayarao M, Chin LS. Robotics and its applications in stereotactic radiosurgery. *Neurosurg Focus* 2007; 23 (6): E6.
10. Andrews DW, Bednarz G, Evans JJ, Downes B. A review of 3 current radiosurgery systems. *Surg Neurol* 2006; 66 (6): 559-564.
11. Hazard L, Wang B, Skidmore TB, et al. Conformity of LINAC-based stereotactic radiosurgery using dynamic conformal arcs and micro-multileaf collimator. *Int J Radiat Oncol Biol Phys* 2009; 73: 562-570.
12. Chen JC, Girvigian MR. Stereotactic radiosurgery: instrumentation and theoretical aspects - part 1. *Perm J* 2005; 9 : 23-26.
13. Jensen RJ, Wendland MM, Chern S, Shrieve DC. Novalis intensity-modulated radiosurgery: Methods for pre-treatment planning. *Neurosurgery* 2008; 62: A2-A9.
14. Amendola BE, Wolf AL, Coy SR, Amendola M, Bloch L. Gamma knife radiosurgery in the treatment of patients with single and multiple brain metastases from carcinoma of the breast. *Cancer J* 2000; 6: 88-92.
15. Gerosa M, Nicolato A, Foroni R, et al. Gamma knife radiosurgery for brain metastases: a primary therapeutic option. *J Neurosurg* 2002; 97 (5 Suppl): 515-524.
16. Gerosa M, Nicolato A, Foroni R, Tomazzoli L, Bricolo A. Analysis of long-term outcomes and prognostic factors in patients with non-small cell lung cancer brain metastases treated by gamma knife radiosurgery. *J Neurosurg* 2005; 102 (Suppl): 75-80.
17. Hasegawa T, Kondziolka D, Flickinger JC, Germanwala A, Lunsford LD. Brain metastases treated with radiosurgery alone: an alternative to whole brain radiotherapy? *Neurosurgery* 2003; 52: 1318-1326.
18. Hoffman R, Sneed PK, McDermott MW, et al. Radio-surgery for brain metastases from primary lung carcinoma. *Cancer J* 2001; 7: 121-131.
19. Lippitz BE, Kraepelien T, Hautanen K, et al. Gamma knife radiosurgery for patients with multiple cerebral metastases. *Acta Neurochir Suppl* 2004; 91: 79-87.
20. Nam TK, Lee JI, Jung YJ, et al. Gamma knife surgery for brain metastases in patients harboring four or more lesions: survival and prognostic factors. *J Neurosurg* 2005; 102 (Suppl): 147-150.
21. Pan HC, Sheehan J, Stroila M, Steiner M, Steiner L. Gamma knife surgery for brain metastases from lung cancer. *J Neurosurg* 2005; 102 (Suppl): 128-133.
22. Petrovich Z, Yu C, Giannotta SL, O'Day S, Apuzzo ML. Survival and pattern of failure in brain metastasis treated with stereotactic gamma knife radiosurgery. *J Neurosurg* 2002; 97 (5 Suppl): 499-506.
23. Serizawa T, Saeki N, Higuchi Y, et al. Gamma knife surgery for brain metastases: indications for and limitations of a local treatment protocol. *Acta Neurochir (Wien)* 2005; 147: 721-726.
24. Sheehan JP, Sun MH, Kondziolka D, Flickinger J, Lunsford LD. Radiosurgery for non-small cell lung carcinoma metastatic to the brain: long-term outcomes and prognostic factors influencing patient survival time and local tumor control. *J Neurosurg* 2002; 97: 1276-1281.
25. Simonova G, Liscak R, Novotny J Jr, Novotny J. Solitary brain metastases treated with the Leksell gamma knife: prognostic factors for patients. *Radiother Oncol* 2000; 57: 207-213.
26. Kondziolka D, Mathieu D, Lunsford LD, et al. Radiosurgery as definitive management of intracranial meningiomas. *Neurosurgery* 2008; 62: 53-8; discussion 58-60.
27. Lee JY, Niranjan A, McInerney J, Kondziolka D, Flickinger JC, Lunsford LD. Stereotactic radiosurgery providing long-term tumor control of cavernous sinus meningiomas. *J Neurosurg* 2002; 97: 65-72.
28. Chang SD, Adler JR, Jr. Treatment of cranial base meningiomas with linear accelerator radiosurgery. *Neurosurgery* 1997; 41: 1019-1025.
29. DiBiase SJ, Kwok Y, Yovino S, et al. Factors predicting local tumor control after gamma knife stereotactic radiosurgery for benign intracranial meningiomas. *Int J Radiat Oncol Biol Phys* 2004; 60: 1515-1519.

30. Han JH, Kim DG, Chung HT, et al. Gamma knife radiosurgery for skull base meningiomas: long-term radiologic and clinical outcome. *Int J Radiat Oncol Biol Phys* 2008; 72: 1324-1332.
31. Kreil W, Luggin J, Fuchs I, Weigl V, Eustacchio S, Papefthymiou G. Long term experience of gamma knife radiosurgery for benign skull base meningiomas. *J Neurol Neurosurg Psychiatry* 2005; 76: 1425-1430.
32. Friedman WA, Murad GJ, Bradshaw P, et al. Linear accelerator surgery for meningiomas. *J Neurosurg* 2005; 103: 206-209.
33. Hakim R, Alexander E 3rd, Loeffler JS, et al. Results of linear accelerator-based radiosurgery for intracranial meningiomas. *Neurosurgery* 1998; 42: 446-453; discussion 453-454.
34. Kimball MM, Friedman WA, Foote KD, Bova FC, Chi YY. Linear accelerator radiosurgery for cavernous sinus meningiomas. *Stereotact Funct Neurosurg* 2009; 87: 120-127.
35. Kollová A, Liscák R, Novotný J Jr, Vladyka V, Simonová G, Janousková L. Gamma Knife surgery for benign meningioma. *J Neurosurg* 2007; 107: 325-336.
36. Malik I, Rowe JG, Walton L, Radatz MW, Kemeny AA. The use of stereotactic radiosurgery in the management of meningiomas. *Br J Neurosurg* 2005; 19: 13-20.
37. Propp JM, McCarthy BJ, Davis FG, Preston-Martin S. Descriptive epidemiology of vestibular schwannomas. *Neuro Oncol* 2006; 8: 1-11.
38. Yasargil MG, Curic M, Kis M, Siegenthaler G, Teddy PJ, Roth P. The total removal of craniopharyngiomas: approaches and long-term results in 144 patients. *J Neurosurg* 1992; 73: 3-11.
39. Hoffman HJ, De Silva M, Humphreys RP, Drake JM, Smith ML, Blaser SI. Aggressive surgical management of craniopharyngioma in children. *J Neurosurg* 1992; 76: 47-52.
40. Jalali R, Dutta D, Srinivas C, et al. Micromultileaf collimator-based stereotactic radiosurgery for selected arteriovenous malformations: Technique and preliminary experience. *J Can Res Ther* 2009; 5: 186-191.
41. Zabel A, Milker-Zabel S, Huber P, Schulz-Ertner D, Schlegel W, Debus J. Treatment outcome after linac-based radiosurgery in cerebral arteriovenous malformations: Retrospective analysis of factors affecting obliteration. *Radiother Oncol* 2005; 77: 105-110.
42. Zabel-Du Bois A, Milker-Zabel S, Huber P, Schlegel W, Debus J. Pediatric cerebral arteriovenous malformations: the role of stereotactic linac-based radiosurgery. *Int J Radiat Oncol Biol Phys* 2006; 65: 1206-1211.
43. Friedman WA, Bova FJ, Mendenhall WM. Linear accelerator radiosurgery for arteriovenous malformations: The relationship of size to outcome. *J Neurosurg* 1995; 82: 180-189.
44. Smit LM, Halbertsma FJ. Cerebral cavernous hemangiomas in childhood. *Childs Nerv Syst* 1997; 13: 522-525.
45. Brunereau L, Labauge P, Tournier-Lasserre E, Laberge S, Levy C, Houtteville JP. *Radiology* 2000; 214: 209-216.
46. Robinson JR, Awad IA, Little JR. Natural history of cavernous angiomas. *J Neurosurg* 1991; 75: 709-714.
47. Konan AV, Raymond J, Bourgouin P, Lesage J, Milot G, Roy D. Cerebellar infarct caused by spontaneous thrombosis of a developmental venous anomaly of posterior fossa. *AJNR Am J Neuroradiol* 1999; 20: 256-258.
48. Barker FG, Jannetta PJ, Bissonette DJ, Larkins MV, Jho HD. The long-term outcome of microvascular decompression for trigeminal neuralgia. *N Engl J Med* 1996; 334: 1077-1083.
49. Young RF, Vermeulen SS, Grimm P, Blasko J, Posewitz A. Gamma knife radiosurgery for treatment of trigeminal neuralgia: Idiopathic and tumor related. *Neurology* 1996; 48: 608-614.
50. Anderson VC, Berryhill PC, Sandquist MA, Ciaverella DP, Nesbit GM, Burchiel KJ. High resolution three-dimensional magnetic resonance angiography and three-dimensional spoiled gradient-recalled imaging in the evaluation of neurovascular compression in patients with trigeminal neuralgia: a double-blind pilot study. *Neurosurgery* 2006; 58: 666-673.
51. Burchiel KJ. Abnormal impulse generation in focally demyelinated trigeminal roots. *J Neurosurg* 1980; 53: 674-683.
52. Lunsford LD, Apfelbaum RI. Choice of surgical therapeutic modalities for treatment of trigeminal neuralgia: Microvascular decompression, percutaneous retrogasserian thermal, or glycerol rhizotomy. *Clin Neurosurg* 1985; 32: 319-333.
53. Murali R, Rovit RL. Are peripheral neurectomies of value in the treatment of trigeminal neuralgia? An analysis of new cases and cases involving previous radiofrequency gasserian thermocoagulation. *J Neurosurg* 1996; 85: 435-437.
54. Leksell L. Stereotaxic radiosurgery and trigeminal neuralgia. *Acta Chir Scand* 1971; 37: 311-314.
55. Lippitz BE, Mindus P, Meyerson BA, Kihlström L, Lindquist C. Lesion topography and outcome after thermocapsulotomy or gamma knife capsulotomy for obsessive-compulsive disorder: relevance of the right hemisphere. *Neurosurgery* 1999; 44: 452-458; discussion 458-460.