

## New associated clinical findings in Kindler syndrome: Case report

İbrahim ÖZMEN (\*), Ercan ÇALIŞKAN (\*\*)

### ÖZET

#### Kindler sendromunda yeni bulgular

Kindler sendromu deri frajilitesi ile seyreden, nadir görülen, otozomal resesif bir hastalıktır. İnfantil dönemde travmanın başlattığı vezikül oluşumu, fotosensitivite ve ilerleyici poikiloderma ile karakterizedir. Bunların dışında başka klinik bulgular da tanımlanmıştır. Bu bildiride bilateral meme başı yokluğu ve çift uvula gibi yeni ilave klinik bulguların eşlik ettiği, 21 yaşında Kindler sendromlu bir erkek hasta tanımlandık. Bildiğimiz kadarıyla bu yayın literatürde Kindler sendromuyla ilişkili bu bulguları tanımlayan ilk bildirimdir.

**Anahtar Kelimeler:** Kindler sendromu, çift uvula, athelia.

### SUMMARY

Kindler syndrome is a rare autosomal recessive disorder associated with skin fragility. It is characterized by trauma-induced blistering in infancy, photosensitivity, progressive poikiloderma and extensive skin atrophy. Additional clinical features also described. In this report we described a 21-year-old male patient with Kindler syndrome who had bilateral athelia and double uvula as additional clinical findings. As far as we know, this is the first report in the literature describing these new associated findings in Kindler syndrome.

**Key Words:** Kindler syndrome, double uvula, athelia.

### Introduction

Kindler syndrome is a rare hereditary disorder characterized by acral blister formation in infancy and childhood, progressive poikiloderma and photosensitivity. Since it was first described in 1954, less than 100 cases have been reported worldwide. Herein we report a case of with Kindler syndrome with additional clinical findings which were not described before.

### Case report

21-year-old man was admitted to our outpatient clinic with the complaints of photosensitivity, skin thinning and color change. He had a history of hand and foot blistering starting from birth to the end of childhood. History of photosensitivity had disappeared in his early childhood. There was no similarly affected member in his family and there was no history of consanguineous marriage between his parents. Dermatological examination revealed poikiloderma especially localized on forearms, cigarette paper-like skin atrophy on dorsa of hands and feet, adematoglyphia, dystrophic nail changes, buccal mucosal pigmentation, gingival hypertrophy and edema, multiple permanent teeth loss, double uvula, and bilateral absence of the nipple (athelia) (Figure-1). We noticed syndactyly on his toes and also he had been operated for hand syndactyly in childhood years. All laboratory examinations were within normal limits and it is reported that there was no evidence of stenosis in gastrointestinal examination with barium enema. Histopathologic examination of skin biopsy revealed epidermal atrophy, loss of rete ridges and pigmentary incontinence. He was diagnosed with Kindler syndrome (KS) and advised to use sunscreens and to be examined annually by a dermatologist.

### Discussion

KS is a rare hereditary disorder characterized by acral blister formation in infancy and childhood, progressive poikiloderma, cutaneous atrophy and increased photosensitivity. Additional clinical features include gingival erosions, ocular, esophageal, gastrointestinal and urogenital involvement, and increased risk of mucocutaneous malignancy (1). KS was firstly described by Theresa Kindler in 14-year-old girl as a genetic association of poikiloderma congenitale and epidermolysis bullosa dystrophica or may be previously unreported new syndrome (2). Then Weary et al. described a similar case in the name of hereditary acrokeratotic poikiloderma (3). The genetic defect associated with the syndrome is FERMT1 (also known as KIND1) gene localized on chromosome 20p12.3. This gene encodes a protein, Kindlin I, which plays a regulatory role in

\*Çorlu Military Hospital, Dermatology Service, Tekirdağ, Turkey

\*\*Gülhane Military Medical Academy, School of Medicine, Department of Dermatology, Etilik, Ankara, Turkey

**Ayrı basım isteği:** İbrahim ÖZMEN, MD  
Çorlu Military Hospital  
Dermatology Service, Çorlu/Tekirdağ, Turkey  
e-mail: ibrahimozmen@hotmail.com

Makalenin Geliş Tarihi: 10.06.2013 • Kabul Tarihi: 10.12.2013 • Çevrim İçi Basım Tarihi: 25.10.2015

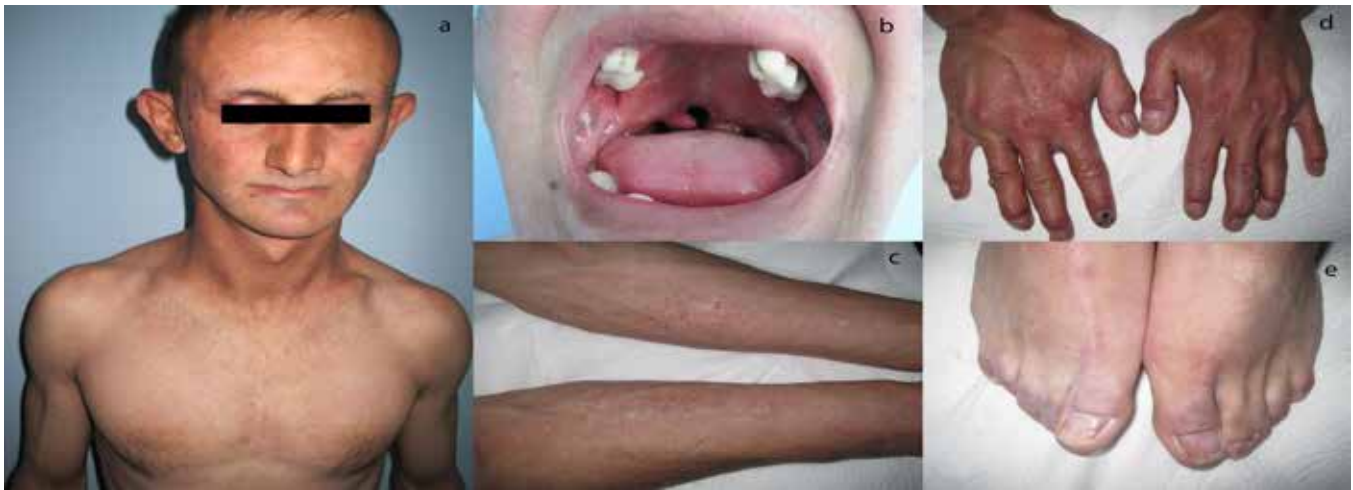
inhibiting over-secretion of basement membrane components by basal keratinocytes at the dermo-epidermal junction (1,4). The largest case series were reported by Penagos et al. with 26 patients (5). To facilitate clinicians in the diagnosis of KS, Fischer et al. proposed a set of clinical diagnostic criteria (6). Acral blistering, progressive poikiloderma, skin atrophy, increased photosensitivity and gingival fragility have been proposed as the major findings and mucosal involvement and syndactyly as minor criteria. They considered that the presence of the 4 major criteria makes the diagnosis of KS certain. The presence of 3 major and 2 minor criteria makes the diagnosis probable and the presence of 2 major criteria and 2 minor criteria or associated symptoms renders the diagnosis likely. As well as all major and minor criteria were present in our case, the other associated findings (nail dystrophy, poor dentition, adermatoglyphia) were also observed.

Commonly seen histological findings with light microscopy are epidermal atrophy, dilatation of blood vessels in the papillary dermis, vacuolar degeneration of basal layer, presence

of cracks in the dermo-epidermal layer and pigmentary incontinence. Transmission electron microscopy of KS skin often shows major disorganization of the basement membrane with extensive reduplication of the lamina densa, focal widening of the lamina lucida, and multiple planes of cleavage (7).

KS must be differentiated from dystrophic EB, Rothmund-Thomson syndrome, hereditary sclerosing poikiloderma and Weary syndrome. Since its description Weary syndrome has been the main differential diagnosis of KS and some cases have even been published as Kindler-Weary syndrome. However there are significant differences between KS and Weary syndrome. Photosensitivity, pronounced in KS, is usually absent in patients with Weary syndrome and blisters are not present shortly after birth but rather appear within the first 6 months of life. Skin atrophy, if present, is not as pronounced as in KS (7).

We desired to report this case because bilateral athelia and double uvula has not been described before as an associated finding in this rarely seen syndrome.



**Figure-1:** Bilateral absence of the nipple (athelia) (a), buccal mucosal pigmentation, multiple permanent teeth loss and double uvula (b), poikiloderma especially localized on forearms (c), cigarette paper-like skin atrophy on dorsa of hands (d), syndactyly (e).

## References

1. Has C, Castiglia D, del Rio M, et al. Kindler syndrome: extension of FERMT1 mutational spectrum and natural history. *Hum Mutat* 2011;32(11):1204-12.
2. Kindler T. Congenital poikiloderma with traumatic bulla formation and progressive cutaneous atrophy. *Br J Dermatol* 1954; 66: 104–11.
3. Weary PE, Manley WF Jr, Graham GF. Hereditary acrokeratotic poikiloderma. *Arch Dermatol* 1971; 103:409–22.
4. Kaviarasan PK, Prasad PV, Shradda, Viswanathan P. Kindler syndrome. *Indian J Dermatol Venereol Leprol* 2005;71:348-50.
5. Penagos H, Jaen M, Sancho MT, et al. Kindler syndrome in Native Americans from Panama: report of 26 cases. *Arch Dermatol* 2004;140:939-44.
6. Fischer IA, Kazandjieva J, Vassileva S, Dourmishev A. Kindler syndrome: a case report and proposal for clinical diagnostic criteria. *Acta Dermatovenerol Alp Panonica Adriat* 2005;14:61-7.
7. Mendes L, Nogueira L, Vilasboas V, Talhari C, Talhari S, Santos M. Kindler syndrome: report of two cases. *An Bras Dermatol* 2012;87(5):779-81.